

Stimulation of bone formation in the expanding mid-palatal suture by transforming growth factor- β_1 in the rat

Masatoshi Sawada and Noriyoshi Shimizu

Department of Orthodontics, Nihon University School of Dentistry at Matsudo, Chiba, Japan

SUMMARY The most intense endogenous transforming growth factor (TGF)- β_1 expression was detected in osteoblasts and fibroblasts in the mid-palatal suture 24 hours after the start of palatal expansion with an immunohistochemical technique. Based on these data, local effects of transforming growth factor- β_1 (TGF- β_1) in the expanding mid-palatal suture of the rat were examined. Single doses of human recombinant (rhu) TGF- β_1 (40 and 200 ng, and 1 μ g) were injected into the expanding mid-palatal suture 24 hours after expansion started. Calcein was also injected immediately, and 6 and 12 days after expansion. The width of each calcein label was measured to evaluate bone formation along the suture with bone histomorphometry. In the experimental groups, bone formation during the 12-day expansion period was stimulated significantly ($P < 0.05$), in a dose-dependent manner, compared with that in the control group. Furthermore, bone formation during the later stage (6–12 days) of the 12-day expansion period, was still significantly higher than that in the control group. In addition, the amount of bone formation in response to a course of 3 injections of 200 ng rhu TGF- β_1 on days 3, 6, and 9 was almost equal to that induced by a single injection of 200 ng rhu TGF- β_1 on day 1. These results suggest that TGF- β_1 may play an important role in bone formation at the active site of the suture in response to rapid palatal expansion and application of TGF- β_1 during the early stages may induce rapid bone formation.

Introduction

The malocclusion caused by a narrow maxillary dental arch width, such as Class I with crowding, Class II with a V-shaped arch, and Class III with a small maxilla in growing patients, is often treated with rapid palatal expansion. This increases the posterior dentition width rapidly, which is followed by active bone formation in the mid-palatal suture. However, the expanded molar width relapses unless followed by a long retention period (Nicholson and Plint, 1989; Sarnäs *et al.*, 1992). Therefore, it is important to characterize the mechanism of active bone formation in the mid-palatal suture in response to expansion, which will help to understand the causes of relapse and develop more effective expansion methods.

Transforming growth factor (TGF)- β_1 is a 25 kDa dimeric protein with multiple functions on cellular growth and differentiation in many cells. Complementary DNA clones have been isolated for five closely related peptides (TGF- β_{1-5}); however, purified or recombinant protein

has been obtained only for TGF- β_{1-3} . Moreover, only TGF- β_{1-3} are found in mammals. Of these, TGF- β_1 , which has been first purified from human platelets, is particularly abundant in bone and platelets in its latent form. After activation, it binds to surface receptors of many cell types, including osteogenic cells (Wakefield *et al.*, 1987) and is suggested to be one of the local regulators of bone formation and resorption (Centrella *et al.*, 1988). Several studies have shown the biological effects of TGF- β_1 on osteogenic cells. In some *in vitro* experiments, TGF- β_1 was found to stimulate collagen synthesis (Centrella *et al.*, 1987), osteopontin, osteonectin (Noda *et al.*, 1988) and fibronectin (Ignatz and Massague, 1986) production and alkaline phosphatase (ALP) activity (Noda and Rodan, 1987) in osteoblast-like cells, but in others TGF- β_1 produced diverse effects (Centrella *et al.*, 1988). In organ culture, TGF- β_1 stimulates bone resorption in mouse calvarial cultures (Tashjian *et al.*, 1985), but inhibits resorption in fetal rat long bone cultures (Pfeilschifter *et al.*, 1988). *In vivo*, human

recombinant (rhu) TGF- β_1 stimulates woven bone formation after injection directly over the calvarial bones of neonatal rats and the bone formative effect is much stronger than that of TGF- β_2 (Noda and Camilliere, 1989; Tanaka *et al.*, 1993). However, in an active bone formation site, such as an expanding suture, effects of TGF- β_1 are still not known. Therefore, in the present study, the expression of TGF- β_1 in response to rapid expansion of the mid-palatal suture was investigated as a preliminary experiment using an immunohistochemical technique, and on the basis of endogenous TGF- β_1 expression observed in a preliminary experiment, rhu TGF- β_1 was injected into the expanding suture in an attempt to evaluate its synergetic effects on bone formation in response to mechanical and biological stimuli.

Materials and methods

(A) Histochemical studies on endogenous TGF- β_1 expression in response to expansion

Animal surgery and treatment. Twenty-five male rats of the Wistar strain, weighing 200 ± 5 g, were used. They were divided into four experimental and one control group. The experimental groups were subjected to expansion for 1, 2, 3, and 5 days. Expansion was carried out as follows: the rats were anaesthetized with an intraperitoneal injection of sodium pentobarbital (1 μ l/g body weight), a hole was drilled laterally in both incisors at the level of the gingival papilla with a No. 1/4 round burr and rapid expansion of the mid-palatal suture was achieved by inserting a 1.5 mm thick circular metal ring between both maxillary incisors. A 0.2 mm diameter round wire was then inserted into the holes and bent to hold the ring between the incisors (Fig. 1). An expansion distance of 1.5 mm between the incisors was found to induce the maximum rate of mid-palatal suture expansion without resulting in any marked body weight decreases (Takahashi, 1990). The rats were weighed every day to determine the effects of surgery and handling.

Preparation of histological sections. After expansion for 1–5 days, all the animals were anaesthetized, as described above, and fixed by transcardial perfusion with 4 per cent (w/v) paraformaldehyde in 0.1 M phosphate buffered saline (PBS). The maxilla, including the mid-

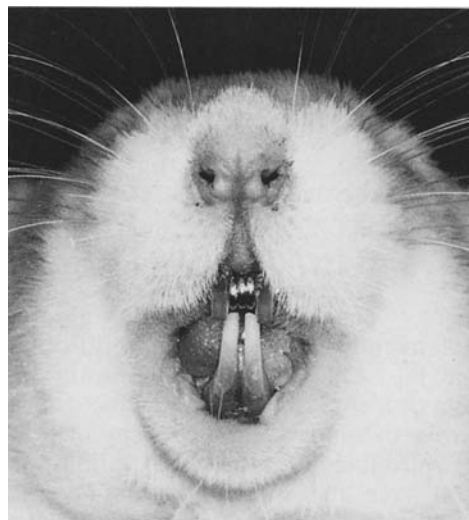


Figure 1 Photograph of a rat subjected to the rapid palatal expansion process, which was performed by insertion and fixation of a 1.5 mm thick circular metal ring between the maxillary incisors.

palatal suture, was removed according to the datum plane (Fig. 2), the tissues were immersed over night in the above fixative at 4°C and then rinsed with PBS. The tissue blocks were demineralized in 10 per cent (w/v) ethylenediaminetetra-acetic acid (EDTA) for 12 days at 4°C, washed thoroughly with PBS, submerged in PBS containing 15 per cent (w/v), followed by 30 per cent (w/v) sucrose for 12 hours each at 4°C, then cut into 10 μ m thick frozen sections in serial order on a cryostat, and mounted on poly-L-lysine coated glass slides (Sigma Chemical Co., St Louis, MO).

Immunohistochemical detection of TGF- β_1 . The protocol used for these studies was a modified version of the method described by Amano *et al.* (1991). A rabbit polyclonal antibody [immunoglobulin (Ig) G fraction] against human TGF- β_1 was purchased from King Brewing (Kokegawa, Japan). Although no experiments were performed on the cross-reactivity of the present antibody against TGF- β_1 in this study, this antibody has been confirmed to react to active form of TGF- β_1 on a Western blot analysis of rat spleen homogenate (Amano *et al.*, 1991). The sections were submerged in PBS for 10 minutes at room temperature, then incubated with 0.3 per cent (v/v) hydrogen peroxide in methanol for 10 minutes

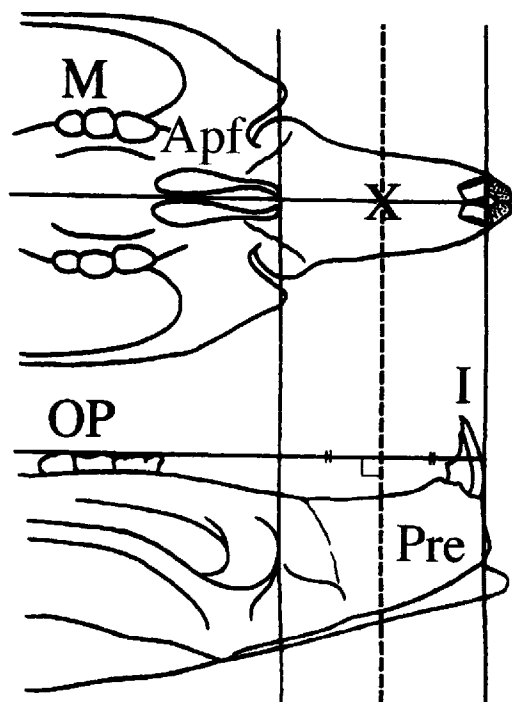


Figure 2 Diagram of the datum plane of a maxillary frontal section. The molar, incisor, premaxillary, occlusal plane, and anterior palatine foramen are indicated as M, I, Pre, OP, and Apf, respectively. The datum plane, used for experiment A and B, is indicated by a dotted line, which crosses perpendicular to the occlusal plane in the centre between the anterior margins of the incisors and Apf. The TGF- β_1 injection site is indicated by X (experiment B).

at room temperature to block the endogenous peroxidase activity. Next they were incubated with 10 per cent (v/v) normal rabbit serum for 20 minutes at room temperature to block non-specific reactions, then with the antibody against TGF- β_1 (2 μ g/ml in PBS) for 60 minutes at room temperature. After washing with PBS, they were reacted with Biotin-labelled goat anti-rabbit IgG at a dilution of 1:60 for 20 minutes at room temperature, and then with avidin-biotinylated peroxidase complex (ABC kit; Vector, Burlingame, CA) for 20 minutes at room temperature. Finally, the sections were developed with 3', 3'-diaminobenzidine tetrahydrochloride in the presence of hydrogen peroxide for 10 minutes at room temperature, then counterstained with haematoxylin.

The nasal septal cartilage, which was present in each section, was used as a positive control, as biologically active TGF- β_1 is known to be

localized in this cartilage (Pelton *et al.*, 1991). Sections treated with normal goat serum instead of the primary antibody were used as negative controls.

Alkaline phosphatase (ALP) and tartrate-resistant acid phosphatase (TRAP) staining. Double staining of these specific marker enzymes (ALP for osteoblasts and TRAP for osteoclasts) was performed using a modified method of that described by Nakamura *et al.* (1991). The substrate solution for TRAP was prepared by dissolving 20 mg naphthol AS-BI phosphate (Sigma, St Louis, MO), the substrate, in 2.0 ml N,N-dimethyl formamide, 10 ml Michaelis-Veronal acetate buffer (0.2 M) and 25 ml distilled water (DW), after which 1.6 ml 1:1 mixture of pararosaniline solution (1 g pararosaniline hydroxychloride in 20 ml distilled water and 5 ml concentrated hydroxychloric acid), 4 per cent (w/v) nitrite solution (70 mg NaNO_2 /1.6 ml DW) and 155 mg L(+)-tartrate were added. The solution was adjusted to pH 5.0 and filtered before use. The substrate solution for ALP was prepared by dissolving 5.0 mg naphthol AS-MX phosphate (Sigma), the substrate, in 0.2 ml N,N-dimethyl formamide, 25 ml Tris buffer (0.2 M), 25 ml distilled water and 30 mg fast blue B salt and filtered before use. The tissue sections were incubated with the ALP substrate solution first, then with the TRAP substrate solution, which contained 20 mM L(+)-tartrate. Both incubations were carried out for 20 minutes at room temperature.

(B) Effect of exogenous TGF- β_1 on bone formation in the expanding suture

Injection of exogenous TGF- β_1 . Human recombinant TGF- β_1 containing 100 μ g/ml bovine serum albumin (BSA) as a carrier protein (King Brewing Co., Ltd., Kakogawa, Japan) was used. The required amount of rhu TGF- β_1 was dissolved in 20 μ l 5 mM HCl and 80 μ l PBS to activate its latent form. Vehicle for use as a control was formulated in the same manner without rhu TGF- β_1 .

In this histomorphometrical study, three experimental groups (five animals per group) were treated with single doses of rhu TGF- β_1 (40, 200 ng/day and 1 μ g/day) and five control animals received vehicle solution. Twenty-four hours after expansion, such as described in animal surgery and treatment, 100 μ l rhu

TGF- β_1 (40–1000 ng) or vehicle was injected into the mid-palatal suture with a microsyringe, as shown by point X in Fig. 2. In the preliminary experiment (A), as the most intense expression of TGF- β_1 in response to rapid palatal expansion was detected 24 hours after expansion, this period was selected as the injection time. A further group of five animals received three injections of 200 ng rhu TGF- β_1 , one each on days 3, 6, and 9. All the animals were injected subcutaneously with calcein (5 mg/kg body weight, Dojin Co., Kumamoto, Japan), a fluorescent indicator, immediately and 6 and 12 days after expansion, and then killed on day 12. Their maxillae, including the mid-palatal sutures were removed, as described above, and immersed in Villanueva bone stain solution (5 mg/ml in 70 per cent methanol, Maruto Instrument Co., Ltd., Tokyo, Japan) for 3 days at 4°C, after which they were embedded in PMMA (polymethylmethacrylate) using routine methods. Three 10- μ m thick frontal sections of the PMMA-embedded bones, including the suture, were taken from each animal for bone histomorphometric analysis.

Bone histomorphometry. All the sections were photographed at the same magnification under a fluorescence microscope and the calcein labels (C_1 , C_2 , and C_3 on days 0, 6, and 12, respectively) were traced, using transparent tracing paper, from the fluoro-photomicrographs (magnified $\times 250$). Calcein labels were traced in the centre. The width of each labelled line along both sides of the suture was measured at 20 vertical levels, at intervals of 20 μ m (5 mm on the magnified fluoro-photomicrograph), with electronic digital calipers (Japan Micrometer MGF Co., Tokyo, Japan). The first level was 100 μ m under the surface of the osseous palate facing the oral cavity (Fig. 3), as the bone formation of the surface area was very irregular and unsuitable for measurement. The mean value of the 40 measurements for both sides was calculated for each section and the mean of this value obtained from three sections was used as the individual average value. The widths of the osteoid seams stained with Villanueva bone stain solution were also measured at the same levels and individual average values calculated in the same manner.

To evaluate measurement error, the calcein labels were traced three times per photomicrograph using five photomicrographs (200 μ m

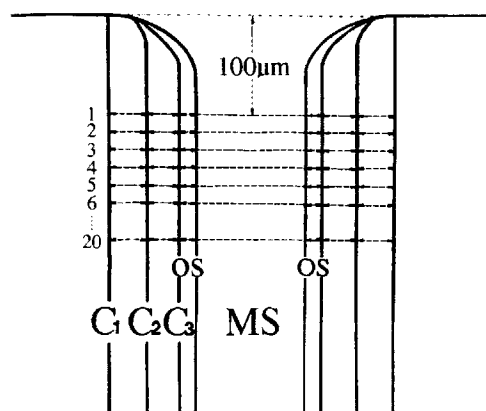


Figure 3 Diagram of an undecalcified frontal section of the rat mid-palatal suture. The calcein labels, mid-palatal suture and osteoid seam are indicated as C_{1-3} , MS, and OS, respectively. Each width between the calcein labels and the osteoid seam width along both sides of the suture was measured at 20 vertical levels, at 20- μ m intervals. The first level was 100 μ m below the surface of the osseous palate.

single injection group) and the width of calcein labels (width between C_1 and C_2) was measured at the first level. The value of the tracing error was less than 0.2 mm.

Statistics. The results were expressed as means \pm standard deviations (SD) and the data were subjected to one-way analysis of variance (ANOVA), as indicated in the results. The LSD method (Fisher) was used to analyse the differences between the control and each experimental group. Differences at $P < 0.05$ were considered to be significant.

Results

(A) Histochemical studies on endogenous TGF- β_1 expression in response to expansion

Body weight changes. The mean weight of the experimental animals on day 1 was approximately 5 per cent lower than their mean starting weight and then increased in parallel to that of the control animals. There were no significant differences between the mean body weights of the control and experimental animals at any time during the study (Table 1).

Immunohistochemical detection of TGF- β_1 . In the control group, the endothelial cells lying inside the blood vessels showed weak TGF- β_1 activity expression, but no TGF- β_1 expression

Table 1 Effects of rapid expansion on body weight (BW) of rats

	Rats	Day 0	Day 1	Day 2	Day 3	Day 5
BW (g)	Control animals	212.3 \pm 6.4	215.3 \pm 4.6	218.7 \pm 4.2	223.3 \pm 4.1	234.7 \pm 5.0
	Experimental animals	215.3 \pm 5.5	206.3 \pm 8.5	210.3 \pm 3.1	216.7 \pm 3.1	223.3 \pm 6.4

Data are expressed as mean \pm SD for five animals. There were no significant differences between the control and experimental groups at any time point during the study.

was seen in the osteoblasts in the osteogenic zone of the suture or the fibroblasts along the transverse fibres (Fig. 4A).

In all the experimental groups, rapid palatal expansion resulted in connective tissue extension, but the sutures were not infiltrated with inflammatory cells. On day 1, marked expression of TGF- β_1 activity in response to rapid palatal expansion was detected in osteocytes, endothelial cells lying inside the blood vessels and in the osteoblasts in the osteogenic zones of the sutures. Strong TGF- β_1 activity expression in the fibroblasts in the mid-palatal suture was also present (Fig. 4B). On day 2, the intensity and localization of TGF- β_1 expression in the suture was similar (Fig. 4C), whereas the TGF- β_1 activity on day 3 was much lower than on days 1 and 2 (Fig. 4D), and had declined to the control level by day 5 (Fig. 4E).

The nasal septal cartilage used as a positive tissue control showed very intense immunostaining for TGF- β_1 in the chondrocytes and perichondrium surrounding the cartilage (Fig. 5A). In the negative control tissues, no immunoreactivity for TGF- β_1 was present in any structures (Fig. 5B).

ALP and TRAP staining. In the control group, low levels of ALP staining of osteoblasts were observed in the osteogenic zone, whereas there were no TRAP-positive cells in the suture (Fig. 6A). In the experimental groups, the ALP staining intensity of the osteoblasts in the osteogenic zone on day 1 was higher than that in the control group (Fig. 6B). The ALP activity in the osteogenic zone increased progressively, reached its maximal level on day 5 (Fig. 6C–E) and was maintained thereafter. In contrast, no TRAP-positive cells were observed along the bone surface during expansion (Fig. 6B–E).

(B) Effect of exogenous TGF- β_1 on bone formation in the expanding suture

Body weight changes. There were no significant differences between the body weights of

any of the groups treated with TGF- β_1 and control vehicle (data not shown).

Stimulation of bone formation by TGF- β_1 . Both the single and course of 3 rhu TGF- β_1 injections stimulated bone and osteoid formation in the mid-palatal suture. The bone that formed in response to rhu TGF- β_1 was well mineralized, which was shown by Villanueva bone staining (Fig. 7A,B). Figure 8 (A) shows the bone formation width data after a single injection of vehicle, 40 and 200 ng, and 1 μ g rhu TGF- β_1 on day 1 and the course of three injections (200 ng rhu TGF- β_1 each) on days 3, 6, and 9 into the rat mid-palatal suture just after the start of rapid palatal expansion. The mean width between C_1 and C_3 in the vehicle-treated group was 40.8 ± 1.0 μ m; those of the single injection groups (40 and 200 ng, and 1 μ g) were significantly greater (57.2 ± 1.6 , 74.8 ± 2.7 and 99.6 ± 3.2 μ m, respectively, $P < 0.05$). The bone formation increased in a dose-dependent manner ($P < 0.05$). The course of three TGF- β_1 injections also stimulated bone formation (mean width between C_1 and C_3 , 75.6 ± 1.2 μ m), which did not differ significantly from that of the 200 ng single injection group (74.8 ± 2.7 μ m). In order to determine how long the TGF- β_1 -stimulated active bone formation continued, bone formation during the early (0–6 days) and late (6–12 days) stages in each group was compared with the corresponding control values. Bone formation during the former (width between C_1 and C_2) and latter (width between C_2 and C_3) stages of expansion increased similarly, compared with the corresponding controls ($P < 0.05$) in a dose-dependent manner. Similar effects of rhu TGF- β_1 on the osteoid tissue were observed. The mean width of the osteoid seam in the vehicle-treated group was 10.1 ± 0.3 μ m. Those of the single injection groups (40 and 200 ng, and 1 μ g) were significantly greater (15.0 ± 0.1 , 17.3 ± 0.4 and 21.2 ± 0.6 μ m, respectively, $P < 0.05$) than the control value. The mean width in the group

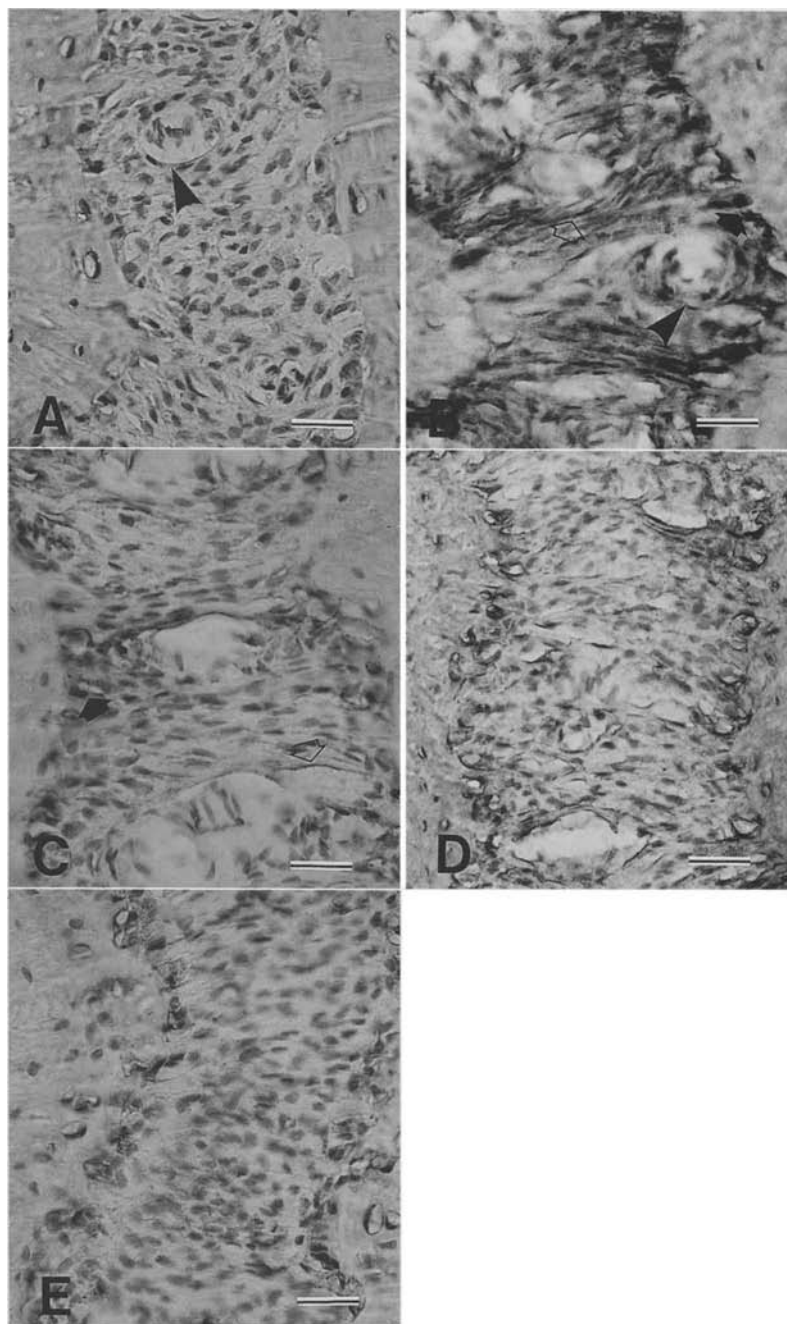


Figure 4 Immunohistochemical staining for TGF- β_1 activity in response to rapid palatal expansion. (A) Weak expression of TGF- β_1 activity in the control group was present in endothelial cells lying inside blood vessels (arrowhead). In the experimental groups, marked TGF- β_1 activity expression was detected on days 1 (B) and 2 (C) in endothelial cells lying inside blood vessels (arrowhead), osteoblasts in the osteogenic zone (closed arrow) and fibroblasts in the connective tissue (open arrow). On day 3 (D), the TGF- β_1 activity decreased rapidly in each type of cell and reached control levels by day 5 (E). (A) control; (B) day 1; (C) day 2; (D) day 3; (E) day 5. (Bar = 30 μ m).

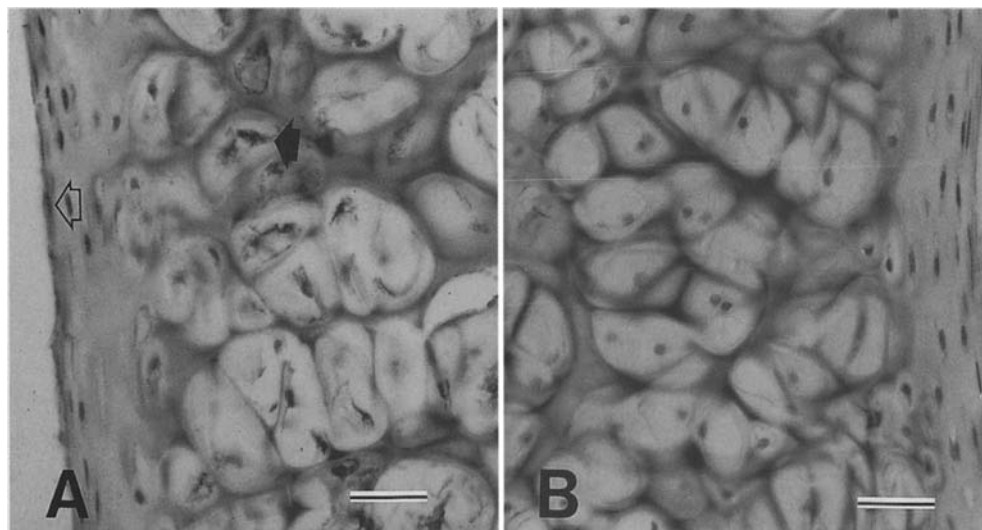


Figure 5 Positive and negative controls. The nasal septal cartilage present in each section was used as a positive control. The negative controls are on the same tissue but treated with normal goat serum instead of the primary antibody. (A) Positive controls: TGF- β_1 was detected in the chondrocytes (closed arrow) and perichondrium (open arrow) surrounding the cartilage. (B) Negative controls: No immuno-reactivity for TGF- β_1 was detected in any structure. (Bar = 30 μ m).

that received the course of three injections was $17.6 \pm 0.4 \mu\text{m}$ (Fig. 8B).

Discussion

The present preliminary experiments demonstrate that high levels of the active form of TGF- β_1 are present in osteoblasts, fibroblasts, and endothelial cells during the early stage (day 1) of mid-palatal suture expansion. TGF- β_1 is secreted as a latent high molecular weight complex from producer cells and it must be activated before it binds to cell surface receptors. *In vitro*, TGF- β_1 is activated by various chemical and enzymatic treatments such as extreme pH values, chaotropic agents, plasmin and glycosidases (Lyons *et al.*, 1990; Miyazono and Heldin, 1989). On the other hand, Oreffo *et al.* (1989) reported that freshly isolated osteoclasts have the capacity to activate the latent form of TGF- β_1 released by bone cultures. These results suggest that activation of the latent form of TGF- β_1 *in vivo* may occur in the acid micro-environment surrounding osteoclasts. However, activation mechanisms of latent form of TGF- β_1 *in vivo* are not clear. In the present study, no TRAP-positive cells were detected around the suture during expansion when marked TGF- β_1 activity expression

was evident. Therefore, it is not likely that the latent form of TGF- β_1 may be activated by a mechanism involving osteoclasts around the suture. Recently, Lyons *et al.* (1994) showed that stimulation of periodontal ligament cells by mechanical stretching led to increased expression of the active form of TGF- β_2 . As mechanical stretching of endothelial cells induced elevation of plasminogen activator mRNA (Diamond *et al.*, 1990), mechanisms involving mechanical cell stretching may be a cause of activation TGF- β_1 via induction of plasmin.

When exogenous rhu TGF- β_1 was injected into the site activated by mid-palatal suture expansion during the early stage, bone formation in the mid-palatal suture was markedly stimulated in a dose-dependent manner. Some studies have shown that continuous application of exogenous TGF- β_1 to the surfaces of neonatal rat calvaria (Mackie and Trechsel, 1990; Noda and Camilliere, 1989) and long bone (Joyce *et al.*, 1990) increased bone formation. In the present study, exogenous application of a single dose of TGF- β_1 to the expanding suture, an active bone formation site, was carried out and bone formation was significantly stimulated approximately 1.5–2.5-fold. Moreover, activation of bone formation by a single rhu TGF- β_1

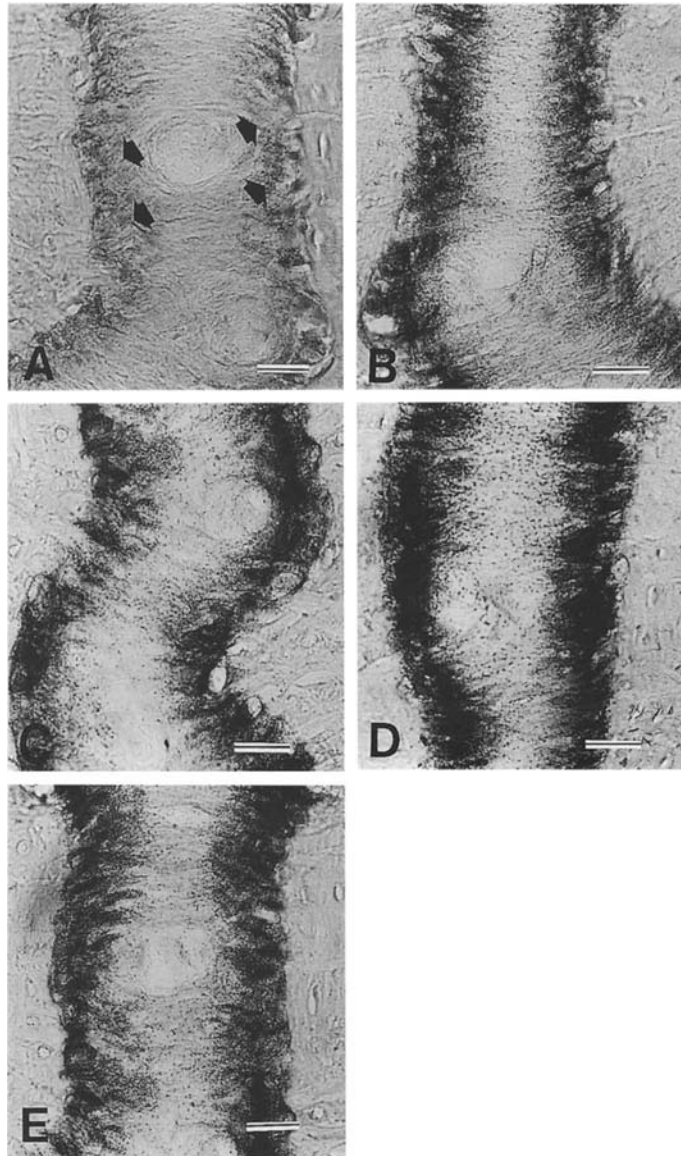


Figure 6 Double staining of ALP and TRAP. (A) Weak ALP staining was observed along the osteogenic zone in the suture (closed arrows), but no TRAP-positive cells were observed in any structure in the control group. In the experimental groups, the ALP activity in the osteogenic zone increased progressively until day 3 (B–D) and was maintained at high levels on day 5 and thereafter (E). No TRAP-positive cells were observed along the bone surface during the expansion period. (A) control; (B) day 1; (C) day 2; (D) day 3; (E) day 5. (Bar = 30 μ m).

injection continued throughout the expansion period in all the experimental groups, with the amount of newly formed calcein-labelled bone (the width between C_2 and C_3) at the late stage (6–12 days) still significantly higher than that of the control group. In addition, the amount

of bone formed (width between C_1 and C_3) after a course of three injections of 200 ng rhu TGF- β_1 on days 3, 6, and 9 was almost equal to that evoked by a single 200-ng injection of rhu TGF- β_1 on day 1, even though the stimulation of bone formation in response to a single

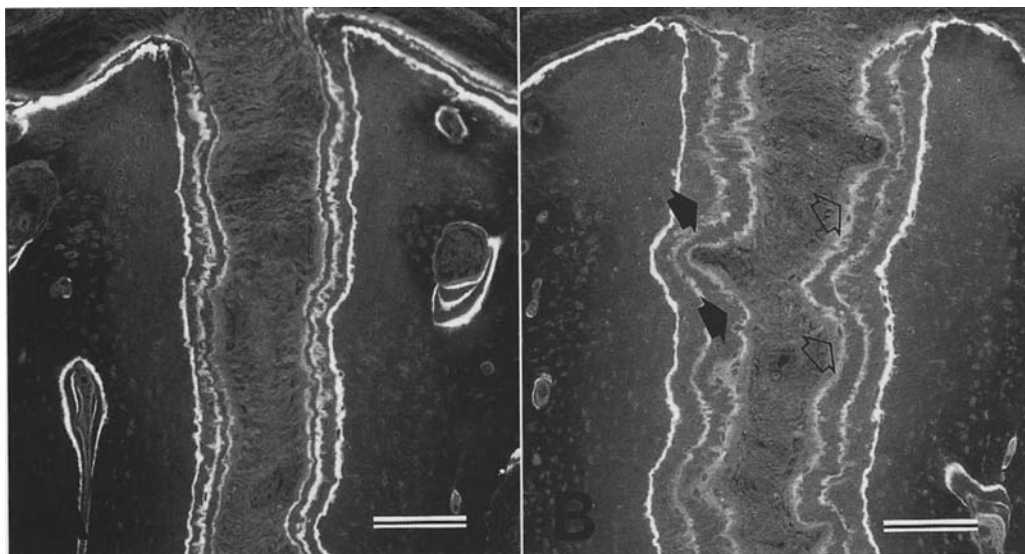


Figure 7 Fluoro-photomicrographs of PMMA-embedded undecalcified sections stained with Villanueva bone stain from the control and 1- μ g TGF- β_1 single injection groups. Bone (closed arrows) and osteoid (open arrows) formation along the expanding mid-palatal suture were stimulated markedly by single injections in a dose-dependent manner compared with the controls. (A) control group; (B) 1 μ g TGF- β_1 single injection group. (Bar = 100 μ m).

injection was dose-dependent. These findings suggest that in an active site where the tensile forces exerted due to expansion and endogenous TGF- β_1 expression were high, TGF- β_1 had a marked stimulatory effect on bone formation at the particular time. It may be a synergetic effect on bone formation in response to mechanical and biological stimuli.

On the other hand, TGF- β_1 has been reported to play a dual role as a bone formation and resorption factor. Shinar and Rodan (1990) used a murine bone marrow culture system and showed that, at low concentrations, TGF- β_1 increased the number of osteoclast-like cells in a concentration-dependent manner with the maximal effect at 100 pg/ml, in response to which a 2–3-fold increase over the control culture value was observed. At higher concentrations, the number of osteoclast-like cells declined rapidly and in the presence of 4 ng/ml, no TRAP-positive cells were detected. Tanaka *et al.* (1993) demonstrated increased numbers of TRAP-positive osteoclasts within neonatal rat parietal bone, but not on the bone matrix

surface, in response to single and repeated injections of 200 ng and 1 μ g rhu TGF- β_1 *in vivo*. Marcelli *et al.* (1990) reported that single and repeated injections of rhu TGF- β_1 (2.5–5 μ g) stimulated the differentiation and proliferation of osteoblasts with consequent stimulation of bone formation in adult mice. Mackie and Trechsel (1990) obtained similar results with growing mice and, in this study, it has been demonstrated that injection of a high dose of rhu TGF- β_1 significantly stimulated bone formation in the growing rat. These studies suggest that application of high doses of TGF- β_1 (40 ng to 5 μ g) may not stimulate osteoclastic activity, but may act as a potent stimulator of osteoblastic cell proliferation and differentiation *in vivo*.

In conclusion, these results suggest that application of TGF- β_1 during the early stage (when marked endogenous TGF- β_1 was expressed in the expanding suture) to the suture activated by rapid palatal expansion, is essential to attain the most effective bone formation in the suture.

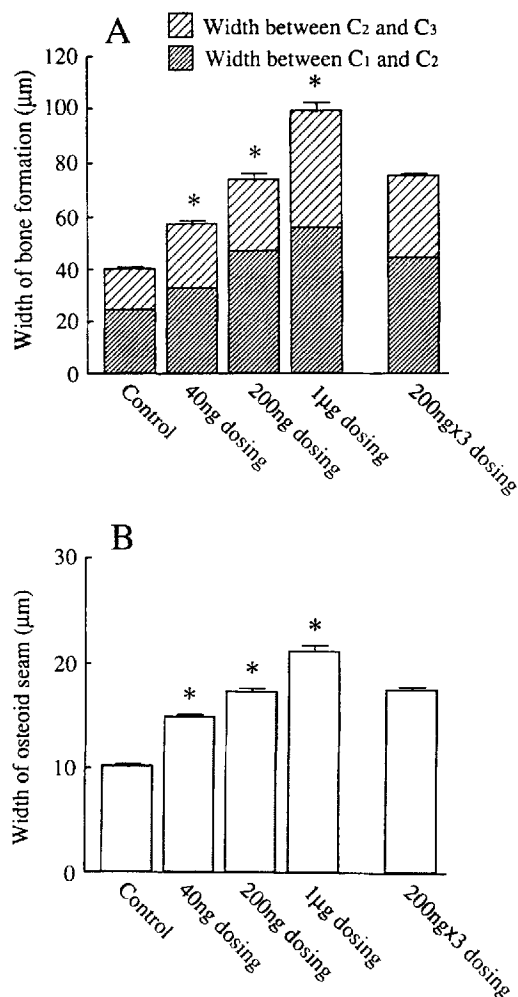


Figure 8 Both the bone formation and osteoid seam widths were increased by the single and course of three injections (200 ng each) of rhu TGF- β_1 into the rat mid-palatal suture. Both parameters were increased significantly in a dose-dependent manner ($P < 0.05$) by the single injections. Neither the difference between the bone formation nor osteoid seam widths in the 200 ng single injection and course of three (200 ng) injection groups differed significantly ($P > 0.05$). In A and B, each column shows the mean \pm SD of five animals. These data were subjected to one-way analysis of variance (ANOVA) and the LSD method (Fisher) was used to analyse the differences between the control and each experimental group.

Address for correspondence

Dr Masatoshi Sawada
Department of Orthodontics
Nihon University School of Dentistry at Matsudo
2-870-1 Sakaecho-Nishi
Matsudo City Chiba 271
Japan

Acknowledgements

The authors are indebted to Professor T. Iwasawa, Department of Orthodontics, and Professor H. Yamamoto, Department of Pathology, Nihon University School of Dentistry at Matsudo, for their advice and criticism.

References

- Amano O, Tsuji T, Nakamura T, Iseki S 1991 Expression of transforming growth factor β_1 in the submandibular gland of the rat. *Journal of Histochemistry and Cytochemistry* 39: 1707-1711
- Centrella M, McCarthy T L, Canalis E 1987 Transforming growth factor β is a bifunctional regulator of replication and collagen synthesis in osteoblast-enriched cell cultures from fetal rat bone. *Journal of Biological Chemistry* 262: 2869-2874
- Centrella M, McCarthy T L, Canalis E 1988 Skeletal tissue and transforming growth factor β . *FASEB Journal* 2: 3066-3073
- Diamond S L, Sharefkin J B, Dieffenbach C, Frasier-Scott K, McIntire L V, Eskin S G 1990 Tissue plasminogen activator messenger RNA levels increase in cultured human endothelial cells exposed to laminar shear stress. *Journal of Cellular Physiology* 143: 364-371
- Ignatz R A, Massague J 1986 Transforming growth factor- β stimulates the expression of fibronectin and collagen and their incorporation into the extracellular matrix. *Journal of Biological Chemistry* 261: 4337-4345
- Joyce M E, Roberts A B, Sporn M B, Bolander M E 1990 Transforming growth factor- β and the initiation of chondrogenesis and osteogenesis in the rat femur. *Journal of Cell Biology* 110: 2195-2207
- Lyons R M, Gentry L E, Purchio A F, Moses H L 1990 Mechanism of activation of latent recombinant transforming growth factor β_1 by plasmin. *Journal of Cell Biology* 110: 1361-1367
- Lyons M S, Richards D W, Kapila S 1994 Mechanically induced expression of TGF- β_2 by periodontal ligament cells. *Journal of Dental Research* 73 (Suppl): 194 (Abstract)
- Mackie E J, Trechsel U 1990 Stimulation of bone formation *in vivo* by transforming growth factor- β : Remodeling of woven bone and lack of inhibition by indomethacin. *Bone* 11: 295-300
- Marcelli C, Yates A J, Mundy G R 1990 *In vivo* effects of human recombinant transforming growth factor β on bone turnover in normal mice. *Journal of Bone and Mineral Research* 5: 1087-1096
- Miyazono K, Heldin C-H 1989 Role for carbohydrate structures in TGF- β_1 latency. *Nature* 338: 158-160
- Nakamura Y, Yamaguchi A, Ikeda T, Yoshiki S 1991 Acid phosphatase activity is detected preferentially in the osteoclastic lineage by pre-treatment with cyanuric chloride. *Journal of Histochemistry and Cytochemistry* 39: 1415-1420
- Nicholson P T, Plint D A 1989 A long-term study of rapid maxillary expansion and bone grafting in cleft lip and

- palate patients. *European Journal of Orthodontics* 11: 186-192
- Noda M, Camilliere J J 1989 *In vivo* stimulation of bone formation by transforming growth factor- β . *Endocrinology* 124: 2991-2994
- Noda M, Rodan G A 1987 Type β transforming growth factor (TGF β) regulation of alkaline phosphatase expression and other phenotype-related mRNAs in osteoblastic rat osteosarcoma cells. *Journal of Cellular Physiology* 133: 426-437
- Noda M, Yoon K, Prince C W, Butler W T, Rodan G A 1988 Transcriptional regulation of osteopontin production in rat osteosarcoma cells by Type β transforming growth factor. *Journal of Biological Chemistry* 263: 13916-13921
- Oreffo R O C, Mundy G R, Seyedin S M, Bonewald L F 1989 Activation of the bone-derived latent TGF beta complex by isolated osteoclasts. *Biochemical and Biophysical Research Communications* 158: 817-823
- Pelton R W, Saxena B, Jones M, Moses H L, Gold L I 1991 Immunohistochemical localization of TGF β_1 , TGF β_2 , and TGF β_3 in the mouse embryo: Expression patterns suggest multiple roles during embryonic development. *Journal of Cell Biology* 115: 1091-1105
- Pfeilschifter J, Seyedin S M, Mundy G R 1988 Transforming growth factor beta inhibits bone resorption in fetal rat long bone cultures. *Journal of Clinical Investigation* 82: 680-685
- Sarnäs K-V, Björk A, Rune B 1992 Long-term effect of rapid maxillary expansion studied in one patient with the aid of metallic implants and roentgen stereometry. *European Journal of Orthodontics* 14: 427-432
- Shinar D M, Rodan G A 1990 Biphasic effects of transforming growth factor- β on the production of osteoclast-like cells in mouse bone marrow cultures: the role of prostaglandins in the generation of these cells. *Endocrinology* 126: 3153-3158
- Takahashi O 1990 Histological investigations on the effect of interrupted expansion force applied to the midpalatal suture in the rat. *Nihon University Journal of Oral Science* 16: 212-236
- Tanaka T, Taniguchi Y, Gotoh K, Satoh R, Inazu M, Ozawa H 1993 Morphological study of recombinant human transforming growth factor β_1 -induced intramembranous ossification in neonatal rat parietal bone. *Bone* 14: 117-123
- Tashjian A H, Voelkel E F, Lazzaro M, Singer F R, Roberts A B, Derynck R, Winkler M E, Levine L 1985 α and β human transforming growth factors stimulate prostaglandin production and bone resorption in cultured mouse calvariae. *Proceedings of the National Academy of Sciences of the United States of America* 82: 4535-4538
- Wakefield L M, Smith D M, Masui T, Harris C C, Sporn M B 1987 Distribution and modulation of the cellular receptor for transforming growth factor-beta. *Journal of Cell Biology* 105: 965-975